

# Non-healing venous leg ulcer

Author: Windy Cole, DPM



## HISTORY

85-year-old male with a non-healing venous ulcer on the inner aspect of his left leg. Duration of ulceration is 64 weeks. Past medical history includes peripheral venous

disease, venous insufficiency, venous stasis dermatitis, non-insulin diabetes, hypertension, and degenerative joint disease.



## PREVIOUS MANAGEMENT

Due to the venous nature of the ulceration the wound has been managed with compression therapy with the inclusion of advance wound dressings as the wound bed appearance indicated. This has included iodine, silver, alginates, collagen, and foam dressings as well as Santyl and Medihoney. Unfortunately, the wound had

never progressed to a healing trajectory and remained static.

On presentation the wound measured 9.2 cm x 2.8 cm x 0.2cm with the wound bed being 80% covered with sloughy non-viable tissue. An ABI was performed and recorded at 1.07 which is within the normal parameters.

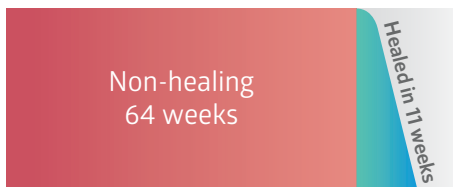

## NATROX<sup>®</sup> OXYGEN WOUND THERAPY

After discussion with the patient it was decided to commence NATROX<sup>®</sup> Oxygen Wound Therapy in conjunction with his compression therapy. Although most of the wound bed was covered with slough it was a thin layer and predominately transparent

and unlikely to impede the flow of oxygen to the wound bed. The therapy plan was to monitor the wound on a weekly basis in the clinic for signs of progression. By 3 weeks of therapy the wound bed was completely free of slough and there were signs of active granulation. The peri wound skin was slightly excoriated due to the level of exudate and the patients underlying dermatitis. 2 weeks later the excoriation had resolved and there was a significant reduction in wound size. Following a total of 11 weeks therapy with NATROX<sup>®</sup> the wound was completely healed.

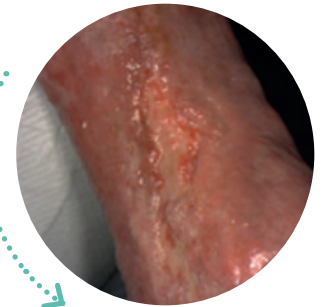
Commenced  
NATROX<sup>®</sup>



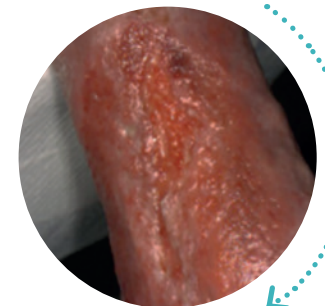
## CONCLUSION

Considering this wound had been present for 15 months healing it in less than 3 months was remarkable. Due to the simplicity of the device and the minimum

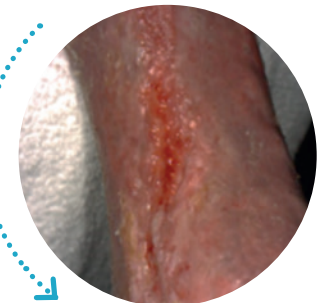
impact it has on patient's lifestyle concordance is rarely problematic even if required for a prolonged period.



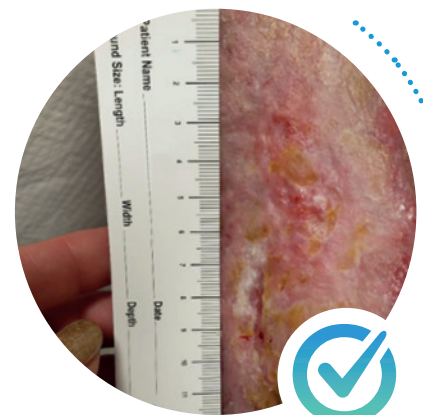
Commenced NATROX<sup>®</sup>



3 weeks of NATROX<sup>®</sup> therapy

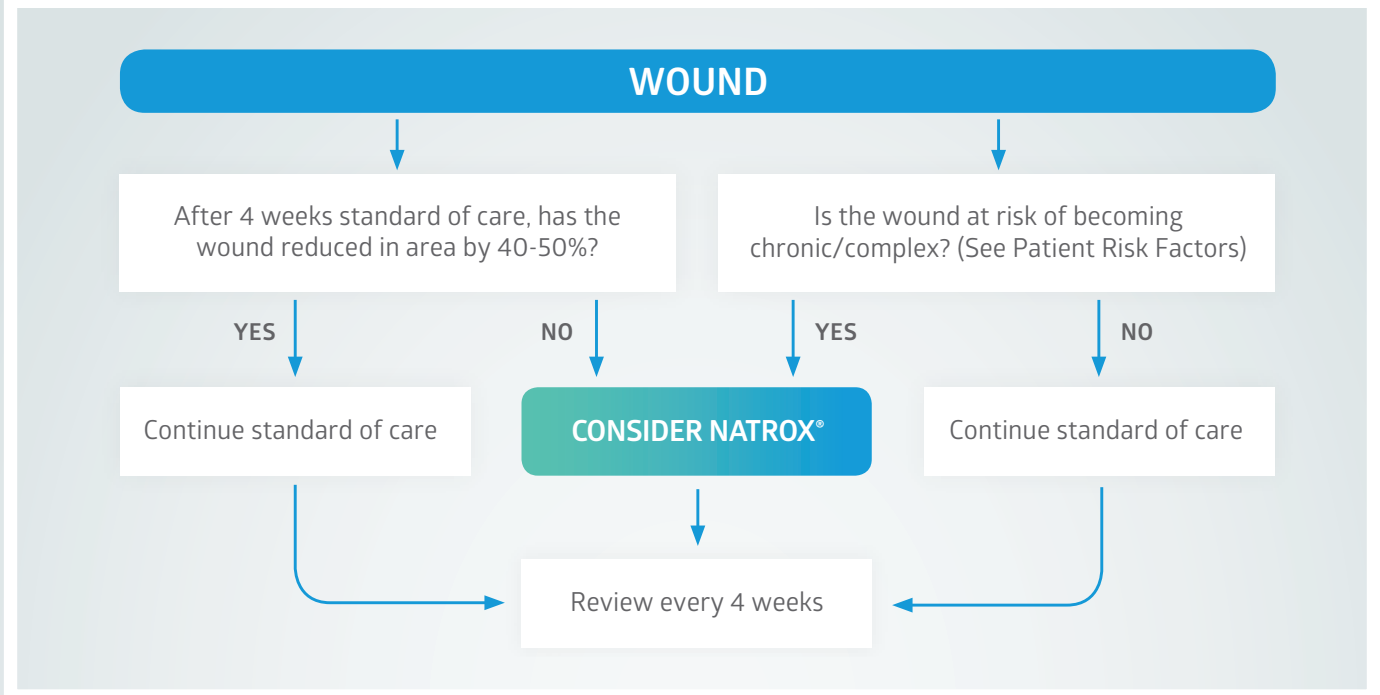


5 weeks of NATROX<sup>®</sup> therapy



11 weeks of NATROX<sup>®</sup> therapy, healed

# When to use NATROX® Oxygen Wound Therapy<sup>1</sup>



## Patient Risk Factors when considering NATROX® Oxygen Wound Therapy



To find out more

Call: +44 (0)1223 661830 or email: [info@natroxwoundcare.com](mailto:info@natroxwoundcare.com)

[www.natroxwoundcare.com](http://www.natroxwoundcare.com)

1. Wounds UK (2018), Consensus round table meeting: Portable topical oxygen therapy for healing complex wounds.

