

# Non-healing diabetic foot ulcer

Author: Windy Cole, DPM



## HISTORY

42-year-old female presented with a 14-week history of ulceration on the apex of her left 2nd toe. Past medical history included non-insulin dependent diabetes, chronic obstructive pulmonary disease, hypertension, obesity, fatty liver, sleep apnea and degenerative joint disorder.

The patient also suffered from anxiety and depression, both of which are often documented in diabetic patients with active foot ulcerations. If these conditions are pre-existing, they can be exacerbated in the presence of a foot ulcer.



## PREVIOUS MANAGEMENT

Previous management had included standard of care which consisted of regular debridement and off-loading along with appropriate wound care dressings which had included topical antimicrobials and alginate dressings. Unfortunately, the wound had failed to respond to this management.

On presentation the wound measured 1.0 cm x 0.7 cm x 0.1cm. There were no signs of clinical infection and due to the

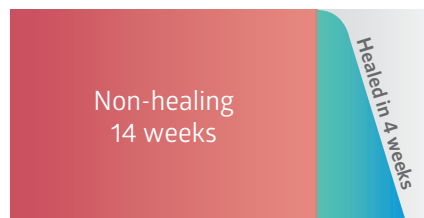superficial depth of the wound there was little risk of osteomyelitis however an x-ray had been performed to confirm this. There was however a moderate level of peri-wound maceration which if not managed appropriately could lead to further breakdown. ABI was performed and was within normal parameters at 1.19. Following effective debridement, it was decided to commence the patient on NATROX<sup>®</sup> Oxygen Wound Therapy



## NATROX<sup>®</sup> OXYGEN WOUND THERAPY

The patient was reviewed weekly in the clinic and wound progression tracked. Following 3 weeks of NATROX<sup>®</sup> therapy the wound had reduced in size and the wound bed was completely free of slough. The peri-wound skin was healthier with no evidence of maceration. Following a further week of NATROX<sup>®</sup> therapy the wound was completely healed.

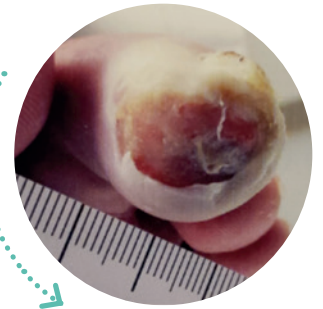
Commenced NATROX<sup>®</sup>



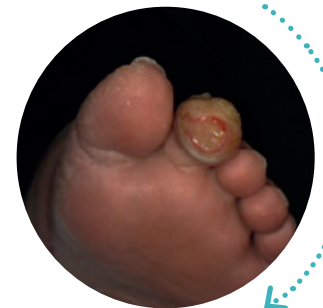## CONCLUSION

This simple device was effective in the management of this patients wound and the clinical outcomes were excellent with complete wound closure occurring in

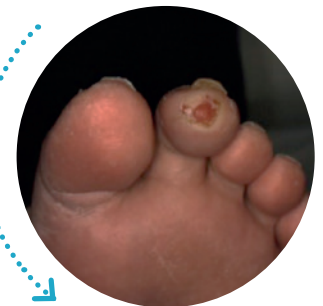4 weeks of therapy. The patient coped extremely well with NATROX<sup>®</sup> on a day to day basis and had no issues incorporating it into their normal routine.



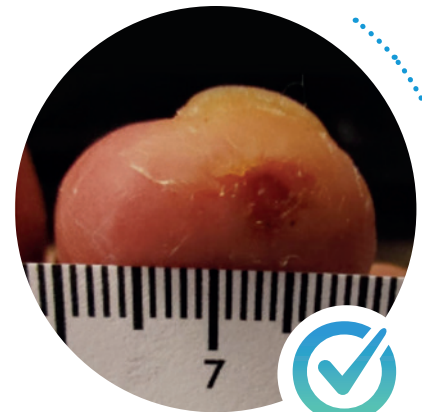
On presentation



Commenced NATROX<sup>®</sup>



3 weeks of NATROX<sup>®</sup> therapy



4 weeks of NATROX<sup>®</sup> therapy, healed

# How to enhance clinical outcomes through increased patient engagement<sup>1</sup>

## ENCOURAGE CONCORDANCE

Management options that reduce the impact on patient lifestyle can improve concordance

## PROMOTE EMPOWERMENT

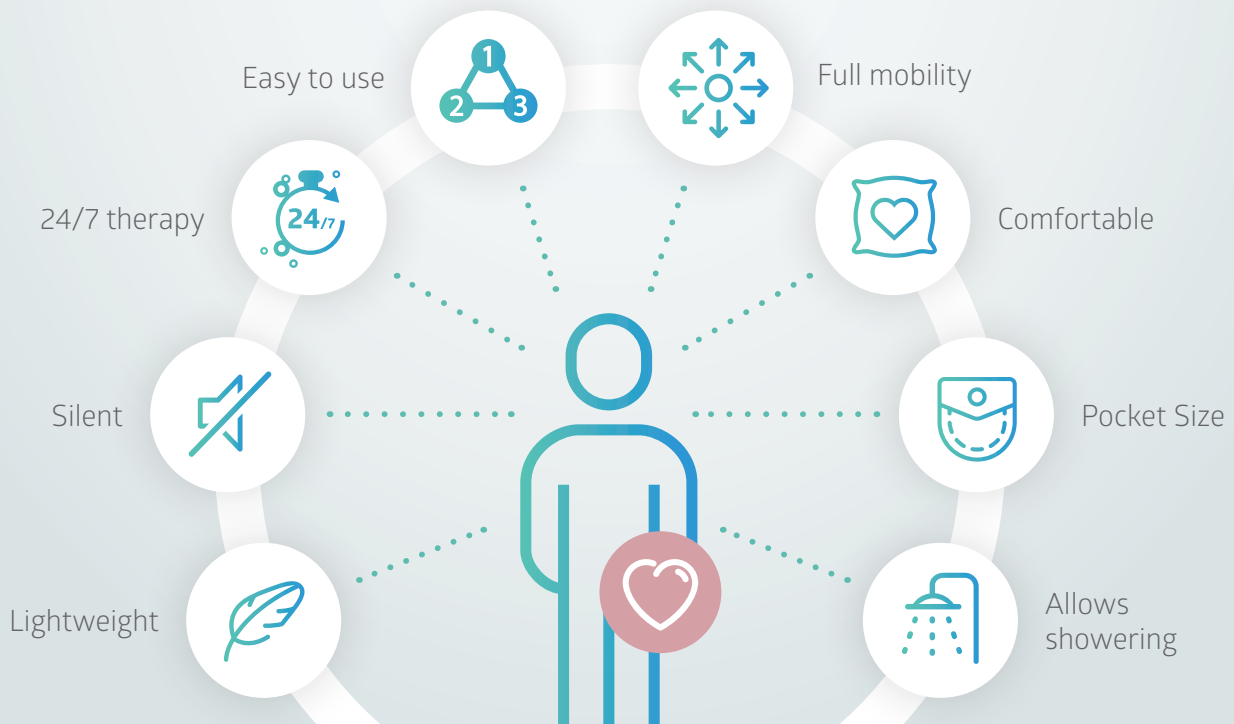
Ensuring that therapy strategies reduce wound symptoms and increase patient well-being

## ENDORSE INVOLVEMENT

Encouraging patient participation and engagement in their own wound care whenever possible

### How can NATROX® help?

## Patient Benefits of NATROX® Oxygen Wound Therapy



To find out more

Call: +44 (0)1223 661830 or email: [info@natroxwoundcare.com](mailto:info@natroxwoundcare.com)

[www.natroxwoundcare.com](http://www.natroxwoundcare.com)

1. Wounds UK (2018), Consensus round table meeting: Portable topical oxygen therapy for healing complex wounds.

